

# Incidentally diagnosed haemangiopericytoma of the hard palate

Gurkan Raşit BAYAR (\*), Tamer ZERENER (\*), Aydın GULSES (\*\*), Omer GUNHAN (\*\*\*)

## ÖZET

### Sert damakta rastlantısal olarak teşhis edilen hemanjioperistoma

Hemanjioperistoma perisitik değişim ile mezenşimal hücrelerden gelişen bir yumuşak doku tümörüdür. Bu tümöre genelde alt ekstremité ve retroperitoneal bölgede, nadiren de baş boyun bölgesinde rastlanır. Bu tümörün tedavisinde cerrahinin altın standart olması yanında, ilave radyoterapi alınmasının da faydalı olacağı ileri sürülmektedir. Biz bu vaka raporu ile 32 yaşında erkek hastada rastlanan hemanjioperistomayı sunmaktayız. Tümör, hastanın oro-nazal açıklığının kapatılması sonrası yapılan takiplerinde rastlantısal olarak fark edilmiştir. Tümörün geniş eksizeyonu yapılmış ve bölgeye radyoterapi uygulanmıştır. Bir yıllık takip sonunda herhangi bir rekürrens ile karşılaşılması. Hemanjioperistoma beklenmeyen prognoz sergileyebilen ve yaşam boyu takip gerektiren az rastlanan vasküler bir tümördür. Nadir rastlanan bu vaka ile ilgili yetersiz bilgi birikiminden dolayı, gelecekte daha fazla klinik vaka raporları ve sistematik derlemelerin yapılması gerekmektedir.

**Anahtar Kelimeler:** hemanjioperistoma, mezenşimal, sert damak, radyoterapi

## SUMMARY

Haemangiopericytoma is a soft tissue tumor derived from mesenchymal cells with pericytic differentiation. This tumor involves mostly the lower extremity and retro peritoneum and rarely the head and neck region. Surgery has been suggested the gold standard of the treatment with additional benefits if radiotherapy is taken. Here, we report the case of a Haemangiopericytoma in a 32-year old male patient. The tumor was discovered incidentally during the follow up clinical examination of his oro-nasal closure. Wide excision of the tumor was performed, and radiation therapy was administered. At the end of the one-year follow up, no recurrence was detected. Haemangiopericytoma is an uncommon vascular tumor with unpredictable behavior, which necessitates a life-long follow up period. Due to the lack of data about this rare entity, further clinical reports and systematic reviews are essential.

**Key words:** haemangiopericytoma, mesenchymal, hard palate, radiotherapy

## Introduction

Haemangiopericytoma (HPC), which was first described by Stout and Murray (1) in 1942, is an uncommon neoplasm of vascular origin. It is a soft tissue tumor, derived from mesenchymal cells with pericytic differentiation (2), which have uniform, ovoid nuclei with indistinct cell borders and are located outside the reticulin sheath of the endothelium. (3) It has been suggested that these ovoid cells are intimately associated with capillaries and possess structural similarity to smooth muscle cells and fibroblasts (2,3).

HPC usually occurs in superficial cutaneous tissues or in muscle segment of the inferior extremities, retroperitoneum and pelvis (4). It accounts for 3% of all tumors in the head and neck (2-4). About 15–20% of HPC cases have been reported in the head and neck region (4), including: the orbit, nasal cavity, paranasal sinuses, nasopharynx, temporal bone, anterior skull, ear, buccal mucosa, lip, floor of the mouth, gingiva, mandible, salivary gland, larynx and tongue (5-15).

HPC of the oral cavity has been reported in the floor of the mouth, gingiva, alveolar-buccal sulcus, mandible and palate (3,12-15). It can occur in any age group, but the most affected age is the fifth and sixth decades (3). No gender predilection has been reported. The etiology of the condition is still unknown; however, an association with trauma has been suggested by Stout and Murray (1). Here, we report the case of a 32-year-old male with a HPC in the hard palate and to our knowledge; this is one of the rare reported cases of HPC of the palate in the literature (5).

## Case Report

A 32-year-old male patient presented to our department with the subjective complaints due to a chronic inflammation of his left upper first molar tooth and a small swelling at the adjacent area of the hard palate. No bleeding and/or fistula were present. According to the patient's history, swelling had appeared around a year previously and it was slowly growing during the last year. The tooth was extracted, and the granulation tissues were curetted. Following the extraction, maxillary sinus perforation occurred and the extraction wound was primarily closed via an intraoral flap rotated from the buccal mucosa. During the postoperative clinical follow-up, it was observed that asymptomatic small swelling on his left hard palate area persisted. Ten days after the extraction, the intraoral examination revealed that the oro-antral opening was successfully closed but the swelling on the hard palate was still present and same in size and shape as before. Clinical examination revealed the presence of a nodular, non-tender lesion, of approximately 2 cm in diameter, with tense-elastic consistency, which was covered with intact mucosa (Figure 1). The mass was relatively mobile in relation to the superficial and deep tissues. The radiographic examination revealed no signs or symptoms of a pathologic alteration. A total removal of the lesion was planned. A wide local excision of the lesion was performed under

\*Gülhane Military Medical Academy, Department of Oral and Maxillofacial Surgery, Ankara/ Turkey.

\*\*Canakkale Military Hospital, Gokceada Surgical Infirmary, Gokceada, Canakkale Turkey.

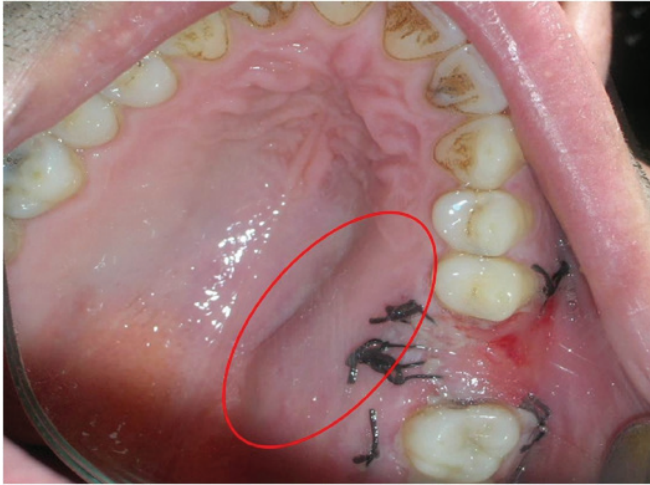
\*\*\*Gülhane Military Medical Academy, Department of Pathology Ankara/ Turkey

**Ayrı basım isteği:** Tamer ZERENER

**Adres:** Gülhane Military Medical Academy, Department of Oral and Maxillofacial Surgery, Ankara/ Turkey.

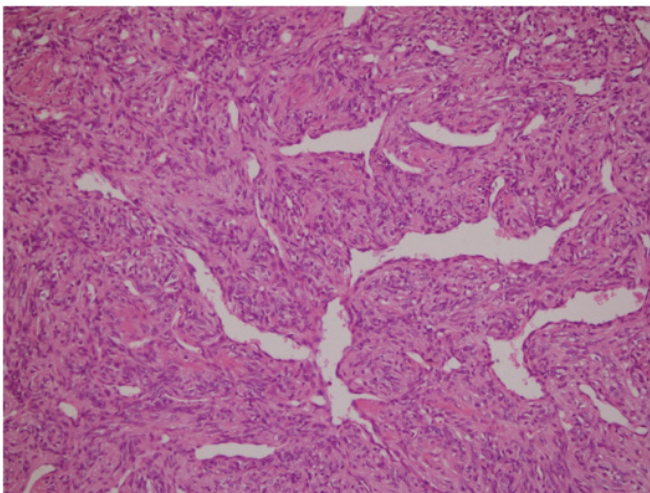
**e-mail:** dttz@mynet.com

**Makalenin Geliş Tarihi:** Nov 12,2012 • **Kabul Tarihi:** Mar 05,2013 • **Çevrim İçi Basım Tarihi:** 30 Haziran 2015



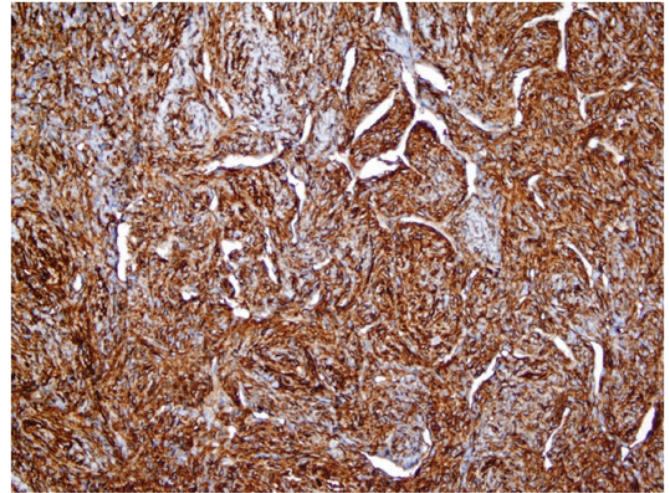
**Figure 1.** Intraoral appearance ten days after tooth extraction and oro antral closure. Please note the swelling on the left side of the palate.

local anesthesia. A palatal mucoperiosteal flap extending from the adjacent upper second molar to the upper canine tooth was elevated and a 2.5 x1.5 x1.0 cm in size and in gum like consistence lesion, which was attached to the bone and soft tissues was removed. The surgical wound was closed via 3/0 silk sutures. The healing period was uneventful. At one-week follow-up, the swelling on the left side of his hard palate was absent. The histopathological examination revealed that the tumor was composed of spindly cells having vesicular fusiform nuclei. There were numerous anastomosing thin wall vascular spaces. Mitotic activity was low. Immunohistochemically, the tumor cells were intensely positive for CD 34 and vimentin. The stainings were negative for smooth-muscle actin, desmin, EMA, CD 31 and cytokeratins (Figure 2-4). Histological and immunohistochemical findings showed that the final diagnosis was an HPC. The margins were clear. However, the number of mitoses was 2 in 20 HPF (High power fields) and the tumor was classified as potentially malignant, which corresponds with the Barnes (12) classification for HPCs. After physical examination, additional staging analyses with computerized tomography (CT) scans of the neck, liver and lungs, bone scintigraphy and abdomen ultrasound were performed due to the possibility of metastases elsewhere in the body. After a consultation with the Department of Oncology, it was decided to perform an adjuvant radiation therapy. A total dose of 50 Gy (200 cGy/day) for 25 days was administered. The patient has

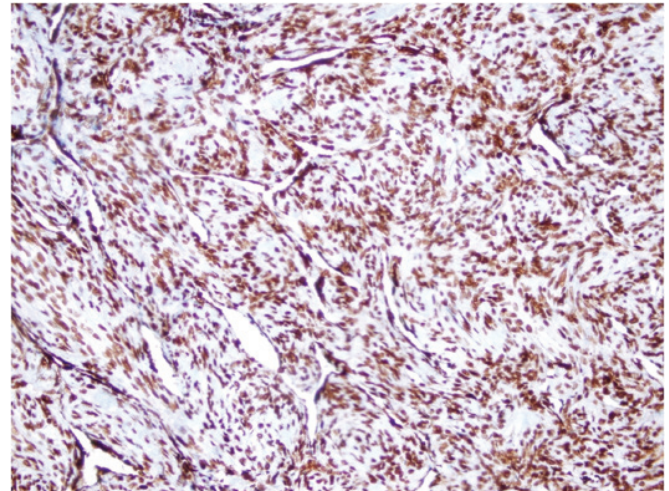


**Figure 2.** Microscopical view of the haemangiopericytoma (HPC) is showing that the tumor is composed of spindly cells having vesicular fusiform nuclei. There are numerous anastomosing thin wall vascular spaces and mitotic activity is low. Hemotoxylin- Eosin staining (HE), original magnification x200.

not shown any signs of recurrence or distant metastases at a one-year follow-up after surgery. Magnetic resonance imaging (MRI) scans of the lower face and neck have also not shown any signs of local recurrence.



**Figure 3.** Immunohistochemically the tumour cells were intensely positive for CD 34. Original magnification x200.



**Figure 4.** Immunohistochemically the tumour cells were negative for smooth-muscle actin. Original magnification x200.

## Discussion

Hemangiopericytomas are rare vascular neoplasms originating in capillary pericytes (1). In the 2002 edition of the WHO classification for soft tissue tumors, HPCs were sub classified into the group of fibroblastic and myofibroblastic soft tissue tumors (3). Similar to the case presented herein, HPC usually presents as a slow growing painless mass associated with only local symptoms. Pain mostly occurs in advanced cases and most often caused by pressure over neurovascular structures (6,7). It has a grey-white or brownish cut surface and its size can range from 1 to 20 cm. (12). In the present case, similar to the formerly presented reports (3), the clinical differential diagnosis was made in particular with peripheral fibroma. It appears as a firm, asymptomatic, sessile or pedunculated swelling, with a color similar to the surrounding tissues and with a palatal exostosis, that is a bony hard nodule covered by intact mucosa and attached to the palatal aspect of the alveolar bone. Due to the lack of the typical clinical signs and symptoms, HPC can be easily overlooked. The diagnosis is made histological (3,7). Microscopically, HPCs consist of tightly packed cells around endothelial lined vascular channels, and electron microscopic evaluation is helpful in



confirmation of the diagnosis (9-12). The electron microscopy shows pericytes surrounding endothelial cells of vessels and preservation of the basement membranes (8). Similar to the first case described by Stout and Murray (1), the current case was also diagnosed incidentally by histopathology examination. The clinicians' awareness of the possible neoplasms during the clinical examination and/or surgical intervention related to the adjacent structures play a key role in the prognosis. According to Barnes (12), HPC's have three types regarding the malignant potential:

- Benign type, in which there are up to one mitosis per 20 HPF (high power fields) and no anaplastic changes.
- Borderline type, which present an increased cellularity with compression of vascular spaces, slight anaplasia and one to four mitoses per 20 HPF.
- Malignant type, which show three or more mitoses per five HPF.

The treatment of haemangiopericytoma is dependent on the amount of mitoses and cellularity with cellular pleomorphism. The more bland lesions with minimal mitotic activity are treated by wide local excision, but the more active and dysplastic lesions are treated by radical surgical excision, with or without adjunctive radiotherapy (10). A chemotherapeutic protocol of cisplatin, cyclophosphamide, adriamycin and vincristine in the treatment of congenital HPC cases (12-14) and interferon alpha therapy in the treatment of unresectable HPC cases have been also advocated. Thiele et al (13) suggested that radical surgical removal of the tumour, followed by an adjuvant external-beam radiation therapy with a local dose of 56 to 66 Gy seems to improve patients' outcome, especially with larger lesions, positive surgical margins and high-grade malignant lesions. However, in a study of Carew et al. (14), the For Peer R relationship between mitosis rate and patient's survival could not be confirmed. In our case, despite the low levels of mitotic activity, because of the lack of a microscopic examination of the resection margins, a dose of 50 Gy adjuvant radiotherapy was administered. The prognosis of HPC is mostly favorable. Surgical resection of this tumor is potentially bedeviled with the risk of torrential haemorrhage, recurrence and metastases. Reported metastases vary from 10% up to 60% (15) and occasionally occur up to 10 years after surgery (13). Metastases of HPC prone to locate in the lungs, liver and bones (3,13). The risk of haemorrhage could be avoided by neoadjuvant embolisation prior to surgical excision of the tumor. This risk of recurrence or metastases may be substantially reduced by wide surgical resection with a careful microscopical examination of the resection margins and the institution of adjuvant radiotherapy in incompletely resected tumors (13). As a conclusion, HPC is an uncommon vascular tumor with unpredictable behavior, which necessitates a life-long follow up period. Due to the lack of data about this rare entity, further clinical reports and systematic reviews are essential.

## References

1. Stout AP, Murray MR. Hemangiopericytoma: a vascular tumor featuring Zimmermann's pericytes. *Annals of Surgery* 1942;116 (1): 26-33.
2. Alabdulhadi K, Burezaq H, Nguyen VH, Bernard C, Manoukian JJ. Extensive tongue hemangiopericytoma in a child: modified combined modality of treatment to preserve well functioning tongue. *Int J Pediatr Otorhinolaryngol* 2004; 68(2): 211-9.
3. Petrone G, Perrotti V, Fioroni M, Rubini C, Piattelli A. Haemangiopericytoma of the maxillary gingiva: report of a case. *J Clin Periodontol* 2005; 32 (8): 921-4.
4. Batsaki JG. Tumors of the head and neck clinical and pathological consideration. 2nd ed. Baltimore, London:

Williams and Wilkins, 1982: 219-312.

5. Carew JF, Singh B, Kraus DH. Hemangiopericytoma of the head and neck. *Laryngoscope* 1999; 109(9): 1409-11.
6. Pandey M, Kothari KC, Patel DD. Haemangiopericytoma—current status, diagnosis and management. *Eur J Sur Oncol* 1997;23(4):282-5.
7. Lin JC, Hsu CV, Jan JS, Chen JT. Malignant haemangiopericytoma of the floor of the mouth—report of a case and review of the literature. *J Oral Maxillofac Surg* 1996;54(8):1020-3.
8. Kothari PS, Murphy M, Howells GL, William DM. Haemangiopericytoma—a report of 2 cases arising on the lip. *Br J Oral Maxillofac Surg* 1996;34(5):454-6.
9. Bertand JC, Guilbert F, Vaillant JM, Szpirglas H, Chomette M, Aurid M. Haemangiopericytoma of orofacial region. *Ann Laryngol Chir Cervico Faciale* 1984;101(8): 607-13.
10. Del Gaudio JM, Garetz SL, Bradford CR, Stenson KM. Haemangiopericytoma of the oral cavity. *Otolaryngol Head Neck Surg* 1996;114(2):339-40.
11. Sharma S, Talukdar P, Singhal BM, Prajapati JA, Goswami JV, Patel JJ, Patel DD. Haemangiopericytoma-base of tongue Oral Oncology EXTRA 2006; 42: 1-4.
12. Barnes L. Tumors and tumor-like lesions of the soft tissues. In: Barnes L. (ed) *Surgical Pathology of the Head and Neck*, 2nd edition. New York: Marcel Dekker Inc, 2001: 890-1048.
13. Thiele OC, Freier K, Flechtenmacher C, Rohde S, Hofele C, Mühling J, Seeberger R. Haemangiopericytoma of the mandible. *J Craniomaxillofac Surg* 2010;38(8):597-600.
14. Carew JF, Singh B, Kraus DH. Hemangiopericytoma of the head and neck. *Laryngoscope* 1999; 109(9): 1409-11.
15. Sikes JW, Ghali GE, Veillon DM, Buchbinder D. Parotid mass in a 62-year-old man. *J Oral Maxillofac Surg* 2003; 61(9): 1073-7.